

Manifestation of Acrylamide induced alterations in the CA1 region of hippocampus of mice by the leaf extract of Meetha Neem : *Murraya koenigii*

*Habiba Bano and Jayanti Jatav

Department of Zoology,
University of Rajasthan,
JAIPUR-302004 (RAJASTHAN) INDIA

*Corresponding Author
E-mail : banohabiba@gmail.com

Received : 02.09.2023; **Accepted** : 01.10.2023

ABSTRACT

A global concern has been observed since the findings about acrylamide formation during high temperature cooking and its presence in infant formulas causing deleterious damage to the vital organs of the body including the major organ brain. Acrylamide is a well-known neurotoxin. It causes alterations and changes in the normal structure of hippocampus. Therefore, there is an urgent need to discover herbal formulation that can combat the toxic effects of acrylamide. Hence, in the present investigation *Murraya koenigii* is used to establish its efficacy as a neuroprotectant against acrylamide damage.

Figures : 08

References : 31

Table : 00

KEY WORDS : Acrylamide, Herbal, Hippocampus, *Murraya koenigii*

Introduction

With the changing lifestyle, food habits of people are also changing leading to the consumption of fast foods, breads and sugar rich food. To add taste and crunch to food numerous chemicals are being added., acrylamide (ACR) being one such. Acrylamide, an industrial chemical is a reactive, highly water-soluble vinyl monomer employed in the manufacture of polyacrylamides which are commonly incorporated in to skin care products such as lotions, cosmetics and deodorants¹². Acrylamide is a potential neurotoxin and a known carcinogen in humans. It is the ingredient of many processed foods such as French fries, chips, bakery items etc. Therefore, it has become an apex of public health concern. According to a report by World Food and Agriculture Organization, the daily consumption of acrylamide from food is a maximum of 0.3-0.8 mg/kg. In reality, more than the average value is consumed by people around the world. Daily consumption of acrylamide by children is 2-3 times more than that of adults as it occurs as a contaminant in baby foods and infant formulas also^{11,26,28}.

Several studies confirm neurotoxicity, carcinogenicity, genotoxicity, reproductive toxicity, immunotoxicity, hepatotoxicity, cardiotoxicity, hematotoxicity, nephrotoxicity, developmental toxicity of acrylamide not only in different organisms but in human

beings also.

Brain is the highest intricate centre of the central nervous system as it is involved in control of all the functions of the body. Hippocampus is an important part of limbic system, located in medial temporal lobe. The primary function of hippocampus is acquisition of memory and consolidation and navigation of spatial memory^{22,25}. Trace amount of acrylamide has been detected in breast milk, while a notable amount of it passes to the developing foetus through placenta³. It causes neurodegeneration and alpha-synuclein accumulation leading to Parkinson disorder¹⁷. Several studies confirm that Acrylamide causes the neurotoxic effects on getting exposed at the workplace¹⁸.

Studies have depicted that sensory, motor and autonomic axons are equally spoiled by acrylamide intoxication in human beings²⁴.

The neurons were characterized by rough, clumped hyperchromatic chromatin with granular / amorphous grey cytoplasm in rats treated with ACR. It is confirmed that ACR affects brain tissue in a degenerative manner^{21,2}.

Commonly known as curry patta or Meetha neem is an aromatic, deciduous shrub or small tree. It possesses anti-diarrheal, antifungal, blood purifying, anti-inflammatory and anti-depressant, antioxidant, lipid-lowering, nephroprotective, neuroprotective, anti-cancer

and antibacterial properties. It also possesses anthelmintic, anti-inflammatory, stimulant and analgesic activities¹. This traditional medicine exhibits various biological activities against neurodegeneration^{4,13}.

The increasing prices of prescription drugs have led the people to look for alternatives. Herbal drugs are more effective, affordable, eco-friendly, free from side effects and available at relatively low cost. They are comparatively safe as compared to synthetic drugs that are regarded to be unsafe to human beings and environment. Hence, this investigation aims to provide valuable insights into acrylamide neurotoxicity and explore the potential protective role of leaf extract of *Murraya Koenigii*.

Experimental Design

Animals

Adult healthy, colony bred, male Swiss albino mice were used in the present investigation. The animals were caged in polypropylene cages under standard laboratory conditions and provided water and pellet diet *ad libitum*.

Experimental Groups

The animals were divided into four groups.,

Group I: Control (distilled water) for 30 days.

Group II: Acrylamide treated (35.6 mg/kg body weight) for 30 days

Group III: Leaf extract of *Murraya* (150 mg/kg body weight) treated for 30 days

Group IV: Pre-treated with *Murraya* (150 mg/kg body weight) for 15 days followed by acrylamide (35.6 mg/kg body weight) and *Murraya* for 30 days (150 mg/kg body weight) and post-treated with *Murraya* (150 mg/kg body weight) again for 15 days (Total 60 days exposure)

Histopathological Study

The hippocampus was dissected out after sacrificing the mice and fixed in the 10% formalin for 24 hrs. After fixation, the tissue was passed in alcohol series for dehydration, cleared in xylene and embedded in paraffin. Serial sections were cut at 10 μ m thickness with rotary microtome and double stained in Hematoxylin Eosin, cleared in xylene and mounted in DPX. The slides were then observed under microscope for photomicrography.

Observations

Following observations were made in CA1 region of hippocampus of mice brain.

Fig. 1 shows the general morphology of hippocampus. All the regions CA1, CA2, CA3, CA4, DG appeared normal.

Fig. 2 is the control group depicting all the 3 layers

POL (Polymorphic Outer Layer), middle PML (Pyramidal Layer) and inner dense ML (Molecular Layer) with normal arrangement of cells. PML shows 5-6 compact layer of small pyramidal cells of CA1 region.

Fig. 3 is acrylamide treated group showing deeply stained glial cells (dg), lightly stained glial cells (lg), presence of vacuoles (V) and dilated blood capillaries (bc) Thickness of pyramidal cell layer decreased to 2 layers. Peri neuronal edema (arrow heads) was observed in this treatment group. Clumping of neurons (f) was also seen in some areas.

Fig. 4 is the *Murraya* treated group administered *Murraya* only for 30 days. The section of this group shows regularly arranged packed cells. The PML display pyramidal cells with big circular vesicular nuclei. Few neurons appear triangular with darkly stained nuclei. Normal blood capillaries (bc) are also seen.

Fig. 5 is the section of the group administered only *Murraya* for 15 days (pretreatment). the section displays normal histological morphology with densely packed neurons in PML quite similar to that of control group.

Fig. 6 belongs to the group administered acrylamide (15 days) after the pretreatment with *Murraya* (15 days). The section display presence of vacuoles (V), deeply stained (dg) and lightly stained (lg) glial cells in POL. Shows degeneration and necrosis in neuronal cells. However, preservation of few pyramidal cells (P) is still observed.

Fig. 7 belongs to the group pretreated with *Murraya* for 15 days followed by acrylamide treatment for 30 days. In this group, multiple necrotic neuromas (arrow heads) with extensive vacuolation (V) have been observed. Shrunken pyknotic nuclei (pn) and dilated blood capillaries (bc) are also seen.

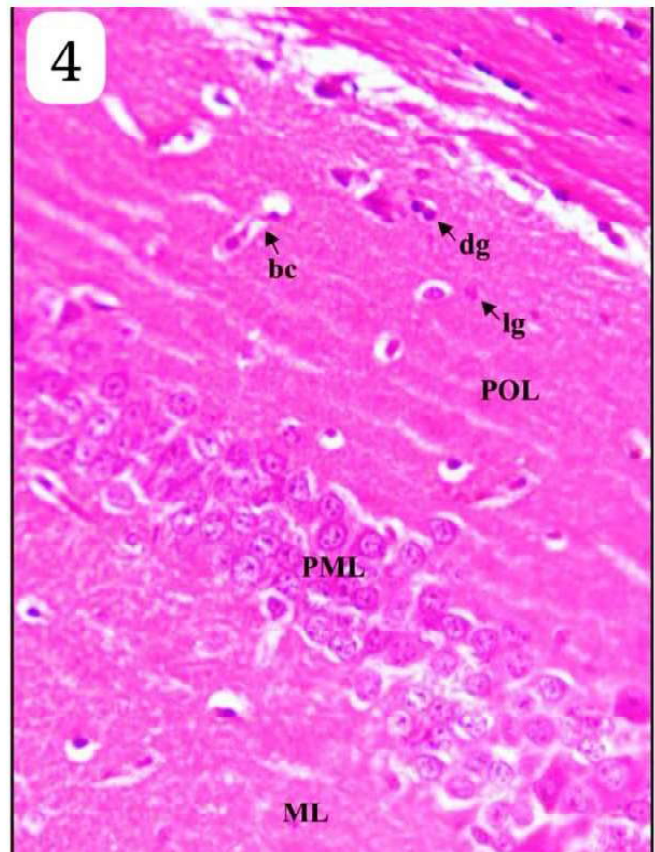
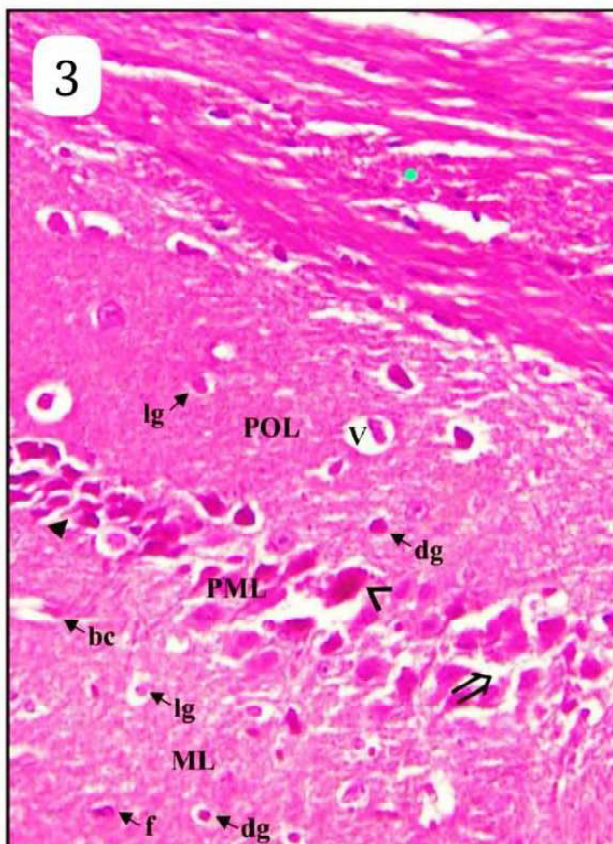
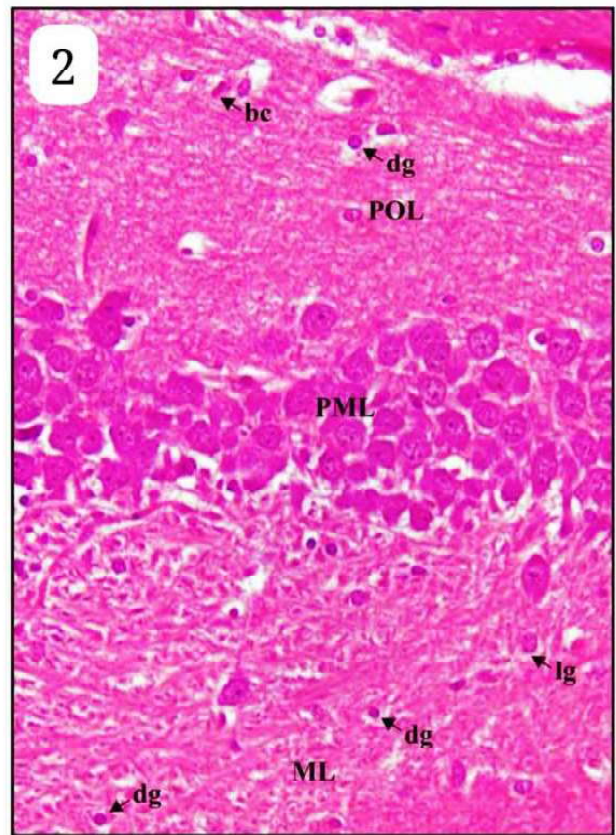
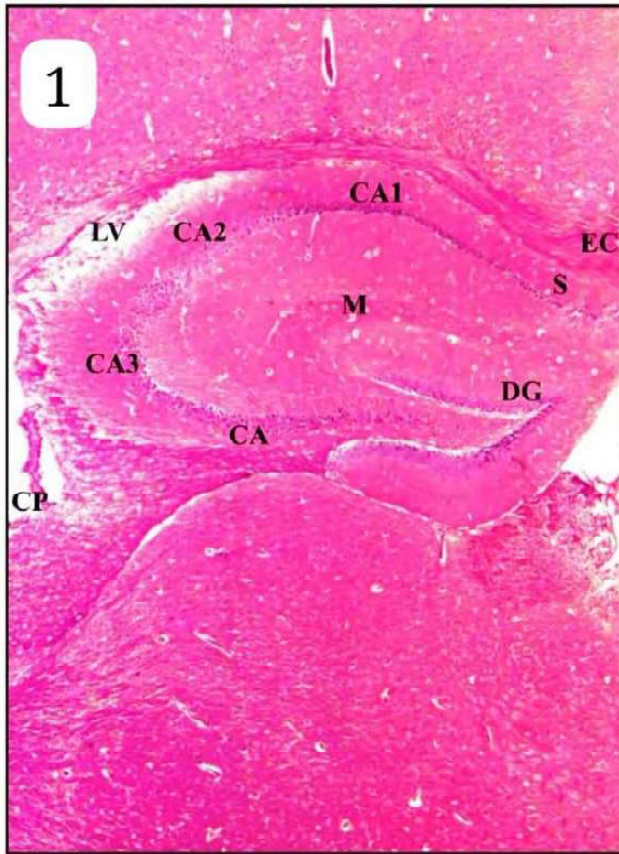
Fig. 8 belongs to the pre-and post-treated group with *Murraya*. The section shows restoration of normal architectural pattern quite similar to that of control group. Preserved pyramidal cells (arrow heads) with normal thickness of layers is also seen.

Result and Discussion

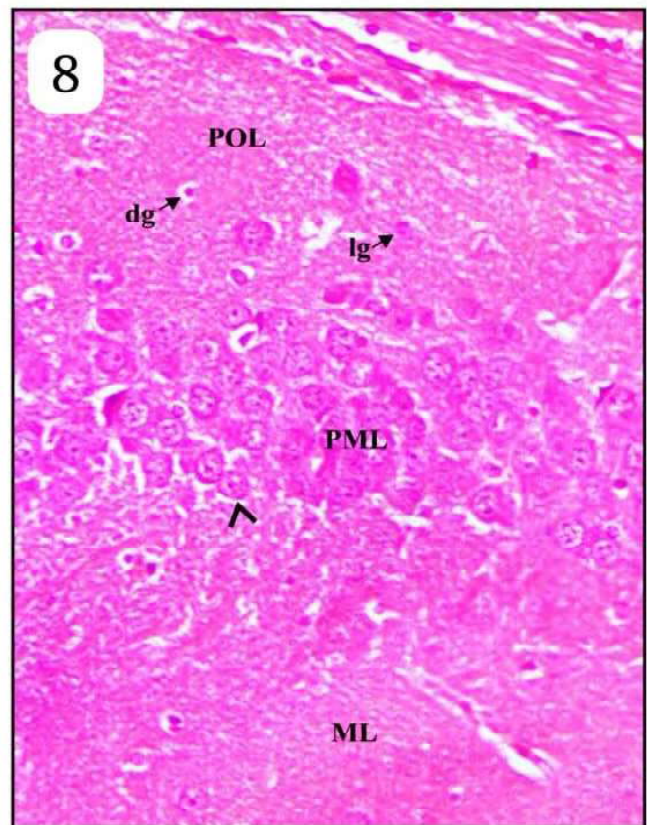
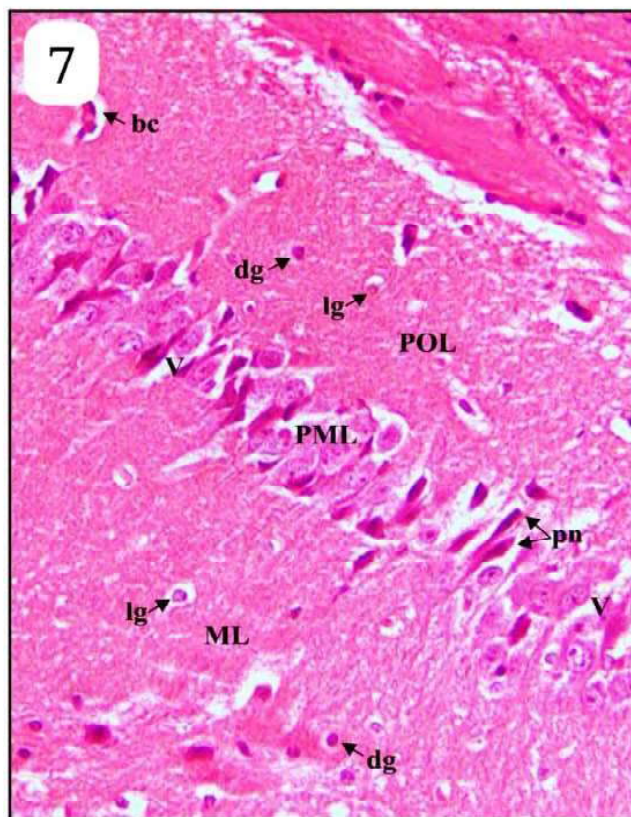
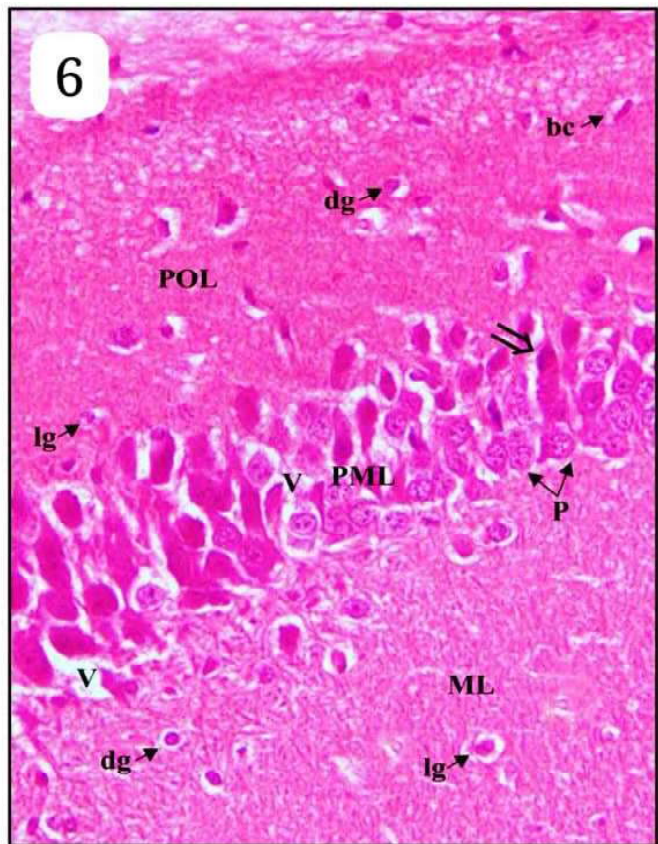
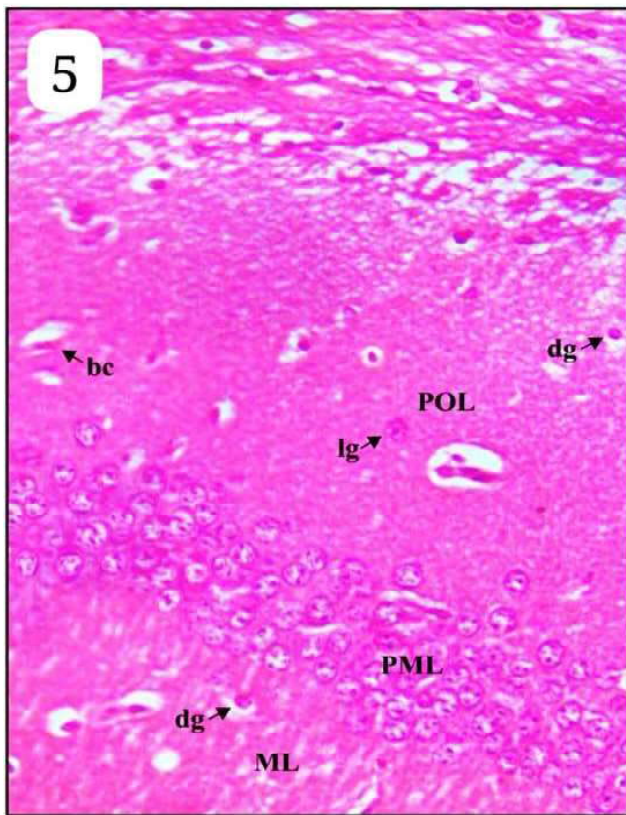
Various studies have been conducted on experimental animals and humans which incline that the brain is principal target organ for AA toxicity²⁷.

It has been reported that AA intoxication at a dose of 10 mg/kg bw/day for 7 weeks leads to glial cell activation²⁹. Arylamide neurotoxicity adversely affect hippocampal neurogenesis and neurocognitive functions¹⁶

There are reports confirming changes in the histology of hippocampal neurons (at all dose levels)



Figs. (1-4) : CA1 region of differently treated groups showing pathological changes. Fig. 1 : Different parts of the hippocampal formation, Fig. 2 : Group I (control), Fig. 3 : Group II (Acrylamide treated), Fig. 4 : Group III (only *Murraya* tracted) H & E X 40).



Figs. (5-8) : Group IV : CA1 region. Fig. 5 : Pretreated with *Murraya* for 15 days. Fig. 6 : Pretreated with *Murraya* for 15 days followed by Acrylamide treatment for 15 days. Fig. 7 : Pretreated with *Murraya* for 15 days followed by Acrylamide treatment for 30 days and Fig. 8 : Post treated with *Murraya* again for 15 days (Total 60 days exposure) (H & E x 40).

and manipulations in number of neurons¹⁵. All these observations are quite similar to the present findings of our study. Marked changes necrosis, presence of vacuoles were observed in rats at a maternal Acrylamide dose starting at 25 mg/kg bw/day, with decreased BDNF levels and induction of oxidative stress¹⁰.

Hippocampus of mice brain after treatment with Acrylamide for 30 days showed alterations in the structure and biochemical properties of CA1 pyramidal neurons which are in support of the present study^{2,21}. Early morphologic studies showed that nerve damage in both the central and peripheral nervous systems was linked to low-dose sub chronic induction of ACR neurotoxicity¹⁹. Massive increases in pyknotic neuronal cells separated by wider gaps, an increase in apoptotic cells, and Purkinje cell and granular neuronal cell death were all observed⁸.

Acrylamide treatment to mothers induces neuronal degeneration in foetal brain tissue, hemorrhagic injury, and a decrease in brain-derived neurotrophic factors levels⁹. The neurotoxic effect of acrylamide on some biochemical parameters such as (BDNF, A β , and IL- 6) and histological deformities and neuronal dysfunction have been indicated in the brain of rats on oral exposure to acrylamide at 50 mg / kg for 21 days were also observed³⁰. Similarly, a reduction in AChE activity in the selected brain structures, such as hemispheres, cerebellum, and brainstem has been observed on acrylamide exposure¹⁴.

As a result of ultrastructural changes in the brain, functional effects may follow. Rats exposed to ACR showed neuronal necrosis in the hippocampus, Purkinje

cell degeneration and granular layer reduction³¹. All these available literatures support the findings of present investigation as massive damage has been observed on acrylamide exposure including degenerated neurons, dilated blood vessels. Pyknotic nuclei and decrease in thickness of layers of CA1 region. (Fig. 2).

Herbal medicines are becoming increasingly popular due to their efficacy, safety, acceptability, and lack of side effects. They have been found to be more compatible with the human body. Traditional medicine is used by approximately 80% of the world's population, according to the World Health Organization (WHO).

Large number of plants have been used to cure many neurodegenerative disorders such as Alzheimer's disease, anxiety, cerebrovascular impairment, stress, seizures, head injury, Parkinson's disease and other memory related disorders⁷. Histopathological features were restored in the hippocampus of rat induced with diabetes on administration of *Murraya koenigii*⁶. A broad range of neurodegenerative disorders, like AD, PD, and others have been found to be treatable on supplementation with *M. koenigii* leaf extracts⁵. *M. koenigii* renders neuroprotection potential against orofacial dyskinesia induced by resperine²³. It has also been reported to improve memory in both young and aged mice²⁰. Similar results have been observed in our present investigation.

Conclusion

From the findings of present investigation, it can be concluded that *Murraya koenigii* renders protection against Acrylamide induced neurotoxicity in the hippocampus of mice.

References

1. Adebajo AC, Olayiwola G, Verspohl EJ, Iwalewa EO, Omisore NOA, Bergenthal D. Evaluation of the ethnomedical claims of *Murraya koenigii*. *Pharm Biol.* 2004; **42**: 610-620.
2. Ahmed HH, Elmegeed GA, El-Sayed ESM, Abd-Elhalim MM, Shousha WG, Shafic RW. Potent neuroprotective role of novel melatonin derivatives for management of central neuropathy induced by acrylamide in rats. *European Journal of Medicinal Chemistry.* 2010; **45**(11): 5452-5459.
3. Annola K, Karttunen V, Keski-Rahkonen P, Myllynen P, Segerback D, Heinonen S, Vahakangas K. Transplacental transfer of acrylamide and glycidamide are comparable to that of antipyrine in perfused human placenta. *Toxicol Lett.* 2008; **182**(1-3):50-6.
4. Azad AK, Babar, ZM, Wan Mohd Azizi WS, Sunzida, NK. The significance of *Murraya koenigii* (L.) Spreng leaves: a mini-review. *PhoL.* 2016; **2**:18-25.
5. Balakrishnan R, Vijayraja D, Jo SH, Ganesan P, Su-Kim I, Choi DK. Medicinal profile, phytochemistry, and pharmacological activities of *Murraya koenigii* and its primary bioactive compounds. *Antioxidants.* 2020; **9**:101.
6. Bhupatiraju L, Bethala K, Wen Goh K, Singh Dhaliwal J, Ching Siang T, Menon S, Menon B, Anchu KB, Yee Chan, S, Chiau Ming L & Khan A. Influence of *Murraya koenigii* extract on diabetes induced rat brain aging. *Journal of medicine and life.* 2023;**16**(2): 307–316.
7. Borgesius NZ, de Waard MC, van der Pluijm I, Omrani A, Zondag GC, van der Horst GT. Accelerated age-related cognitive decline and neurodegeneration, caused by deficient DNA repair. *J Neurosci.* 2011; **31**:12543–12553.

8. El-Sayyad HI, El-Gammal HL, Habak LA, Abdel-Galil HM, Fernando A, Gaur RL, Ouhtit A: Structural and ultrastructural evidence of neurotoxic effects of fried potato chips on rat postnatal development. *Nutrition*. 2011; **27**:1066-1075.
9. Erdemli ME, Turkoz Y, Altinoz E, Elibol E, Dogan Z. Investigation of the effects of acrylamide applied during pregnancy on fetal brain development in rats and protective role of the vitamin E. *Hum Exp Toxicol*. 2016; **35** (12): 1337–1344.
10. Erdemli ME, Aladag MA, Altinoz E, Demirtas S, Turkoz Y, Yigitcan B, Gozukara BH. Acrylamide applied during pregnancy causes the neurotoxic effect by lowering BDNF levels in the fetal brain. *Neurotoxicol Teratol*. 2018; **67**: 37–43.
11. Erkekoglu P, Baydar T. Toxicity of acrylamide and evaluation of its exposure in baby foods. *Nutr Neurosci*. 2010; **23**: 323–333.
12. Exon JH. A review of the toxicology of acrylamide. *J Toxicol Environ Health B Crit Rev*. 2006; **9**(5) : 397-412.
13. Gupta P, Nahata A, Dixit VK, An update on *Murraya koenigii* spreng: a multifunctional Ayurvedic herb, *Zhong Xi Yi Jie He Xue Bao*. 2011; **9**(8) : 824-33.
14. Kopanska M, Czech J, Zagata P, Dobrek L, Thor P Formickig. Effect of the different doses of acrylamide on acetylcholinesterase activity, thiol groups, malondialdehyde concentrations in hypothalamus and selected muscles of mice. *J Physiol Pharmacol*. 2017; **68**(4): 565-571.
15. Lai SM, Gu ZT, Zhao MM, Li XX, Ma YX, Luo L, Liu J. Toxic effect of acrylamide on the development of hippocampal neurons of weaning rats. *Neural Regen Res*. 2017; **12**(10): 1648-1654.
16. Lee JG, Wang YS, Chou CC. Acrylamide-induced apoptosis in rat primary astrocytes and human astrocytoma cell lines. *Toxicol In Vitro*. 2014; **28**(4):562-70.
17. Li J, Li D, Yang Y, Xu T, Li P, He D. Acrylamide induces locomotor defects and degeneration of dopamine neurons in *Caenorhabditis elegans*. *J Appl Toxicol*. 2016; **36**(1):60-7.
18. LoPachin RM. The changing view of acrylamide neurotoxicity. *Neurotoxicology*. 2004; **25**(4): 617–630.
19. LoPachin RM, Ross J F, Lehning EJ. Nerve terminals as the primary site of acrylamide action. *Neurotoxicology*. 2002; **23**: 4359.
20. Mani V., Ramasamy K., Ahmad A., Parle M., Shah S.A.A., Majeed A.B.A. Protective effects of total alkaloidal extract from *Murraya koenigii* leaves on experimentally induced dementia. *Food Chem. Toxicol*. 2012; **50**: 1036–1044.
21. Mannaa F, Abdel-Wahab MA, Ahmed HH, MH Park. Protective role of *Panax ginseng* extract standardized with ginsenoside Rg3 against acrylamide induced neurotoxicity in rats. *J. Appl. Toxicol*. 2006; **26**: 198-206.
22. Moser VC, Anthony DC, Sette WF, MacPhail RC. Comparison of sub chronic neurotoxicity of 2-hydroxyethyl acrylate and acrylamide in rats. *Fundam. Appl. Toxicol*. 1992; **118** : 343–352.
23. Patil R, Dhawale K, Gound H, Gadakh R. Protective Effect of Leaves of *Murraya koenigii* on Reserpine-Induced Orofacial Dyskinesia. *Iran J Pharm Res*. 2012; **11**(2) : 635-41.
24. Pennisi M, Malaguarnera G, Puglisi V, Vinciguerra L, Vacante M, Malaguarnera M. Neurotoxicity of Acrylamide in Exposed Workers. *Int J Environ Res Public Health*. 2013; **10**(9) : 3843–3854.
25. Squire LR, Stark CEL, Clark RE. *Annu. Rev. Neurosci*. 2004; **27** : 279–306.
26. Tian SM, Ma YX, Lou TY, Liu SS, Li GY. Acrylamide neurotoxicity on the cerebrum of weaning rats. *Neural Regeneration Research*.2015; **10** : 938-943.
27. World Health Organization. Acrylamide. World Health Organization. 1985.
28. WHO. Food Safety Programme. Health implications of acrylamide in food. World Health Organization. 2002.
29. Yan D, Pan X, Yao J, Wang D, Wu X, Chen X, Shi N, Yan H. MAPKs and NF- κ B-mediated acrylamide-induced neuropathy in rat striatum and human neuroblastoma cells SY5Y. *J Cell Biochem*. 2019; **120**: 3898–3910.
30. Zaid OA, Sonbaty S, Barakat WE. Ameliorative effect of selenium nanoparticles and ferulic acid on acrylamide-induced neurotoxicity in rats. *Annals of Medical and Biomedical Sciences*. 2017; **3** (2): 35-45.
31. Zhao S, Sun H, Liu Q, Shen Y, Jiang Y, Li Y, Liu T, Liu T, Xu H, Shao M. Protective effect of sea buckthorn berry juice against acrylamide-induced oxidative damage in rats. *Journal of Food Science*. 2020; **85**(7): 2245-2254.